

## Luxation of the Patella

The patella or 'knee cap' is the small bone that connects the thigh muscles to the bones that comprise the shin, namely the tibia and fibula. The term 'luxation' refers to the dislocation of a bone from its normal position. When this happens, it causes pain and lameness, and occurs commonly in small breed dogs, including Westies. In most cases, the patella becomes displaced medially, towards the inside of the leg, rather than laterally (towards the outside of the leg).

While one could easily envision how a traumatic event, like a fall or being hit by a car, could cause dislocation of the patella, in most cases the condition is caused by muscle and skeletal abnormalities present at birth. While the condition can be painful and a cause of lameness, it can be diagnosed and treated effectively in most dogs.

### *How does patellar luxation happen?*

The bones of the knee joint include the thigh bone (femur), the shin bones (tibia and fibula), and the knee cap (patella), which sits in a groove in the femur called the trochlear groove. Ligaments connect these bones and serve to stabilize the joint. The quadriceps muscles are a set of four muscles on the front of the femur that come together near the patella to form the patellar ligament. This ligament can easily be felt between the patella and a prominence on the tibia (tibial tuberosity) over the front of the knee. The quadriceps muscles serve to extend, or straighten, the knee. During this process, the patella acts as a lever arm for the quadriceps and also exerts an even amount of tension from the muscles on the patellar ligament.

Normally functioning knee joints work because all of the components of the knee joint (bones, ligaments, tendons, muscles) are lined up properly. In dogs with congenital patellar luxation, one or more of the components either is malformed,

dysfunctional or becomes so as the dog begins to mature. Some dogs may develop this condition later in life, as a result of trauma or a combination of a congenital abnormality and subsequent wear.

Dogs with luxation of the patella typically have one or more of the following abnormalities: abnormal angulation between the head and shaft of the femur, medial displacement of the quadriceps, lateral twisting or bowing of the femur just above the joint, a shallow trochlear groove, or medial displacement of the tibial tuberosity where the patellar ligament attaches. *Figure 1* on the following page depicts the differences between a normal dog and one with luxation of the patella. In the normal dog, the patella is positioned under the quadriceps femoris muscle and is attached by the patellar ligament to the tibia. In contrast, in the dog with luxation of the patella, the patella and quadriceps are displaced medially.

There are several theories as to which deformity initiates the problem and results in luxation. The most widely accepted theory is that an abnormal angulation between the head and shaft of the femur causes the quadriceps muscle to move medially and pull the patella with it. There are three other theories for the development of the condition. These include 1) hormonal influences on bone formation and growth that result in development of a shallow trochlear groove in the femur, 2) hip diseases that cause dogs to walk abnormally, making the knee compensate inappropriately, and 3) abnormally positioned attachments of the muscles that cause the patella to be displaced medially. It is important to recognize that no single theory explains all cases. Regardless of the underlying cause for patellar luxation, there are several consequences if the condition is not treated. With the patella out of place, the cartilage on the surface of the patella, tibia and femur wears down, causing pain and restricting movement, eventually leading to arthritis. Other problems that may develop include rupture of the cranial cruciate ligament, one of the important

### Common Clinical Findings

Small Breed Dogs

Wide Range of Clinical Signs

Abnormalities in Femur or Tibia

Joint Deformities on Radiographs

ligaments that attach the femur to the tibia. This ligament can be stretched too far and tear completely if the patella is displaced.

Patellar luxation can result in special consequences in dogs that are still growing. For example, a preexisting bone deformity that may be causing the luxation will worsen as the bones continue to grow unless it is corrected surgically. Similarly, without the normal pressure exerted by the patella on the trochlear groove of the femur, the groove does not deepen as it should. As a result, the groove will become too shallow to retain the patella in position, even if it is popped back into place. Consequently, it is very important for an accurate diagnosis to be made and affected dogs receive treatment. This is particularly true for young, growing dogs.

### *Signs and Severity of Patellar Luxation*

Dogs with luxation of the patella may exhibit a variety of clinical signs, depending on the severity of the problem. To clarify and compare the severity of the condition in different dogs, four grades of severity are used. These range from the mildest, Grade I, to the most severe, Grade IV.

**Grade I:** Luxation of the patella in dogs with Grade I typically is discovered during a routine physical examination. In these cases, the patella can be forced out of place manually, but rarely luxates during the dog's regular daily activity. Because all of the components of the joint are normal, dogs with Grade I luxations will appear normal and are not lame.

**Grade II:** Dogs with a Grade II luxation have a mild underlying deformity of the femur. While the patella may be luxated manually, it occasionally may do so on its own. In some dogs, the patella returns to its normal position as the animal moves. In other dogs, the patella will need to be repositioned manually. Dogs with Grade II luxations will occasionally "skip" while walking or running, when the patella has become displaced. Their gait will return to normal when the patella returns to its normal position.

**Grade III:** Grade III luxations are more severe, causing the patella to remain out of position most of the time. The patella can, however, be repositioned manually. The quadriceps muscles in these dogs are displaced medially and bony deformities also are present. Dogs with Grade III luxations may 'skip' like dogs with Grade II luxations, although more frequently. If the patella is luxated more often than it is in its normal position, the dog will develop a 'weightbearing lameness'. This means that the dog will bear some weight on the affected leg, but will walk with a limp.

**Grade IV:** Grade IV luxations are the most severe form of the condition, as the patella is always luxated and cannot be replaced manually. Dogs with Grade IV patellar luxations have significant deformities of the bones and other components that comprise the stifle joint. Affected dogs walk with their hind legs crouched in a permanently flexed position, and are unable to extend their hind legs due to the permanent luxation of the patella.

### *Diagnosis*

The diagnosis of a luxating patella alone is simple, as the patella can be felt or moved out of place during a physical examination. Radiographs will reveal joint deformities and help the veterinarian determine the grade of the luxation. Other orthopedic conditions that often coexist in dogs with luxation of the patella include hip dysplasia, cranial cruciate ligament rupture and Legg-Calvé-Perthes disease (see previous section on *Legg-Calvé-Perthes Disease*).

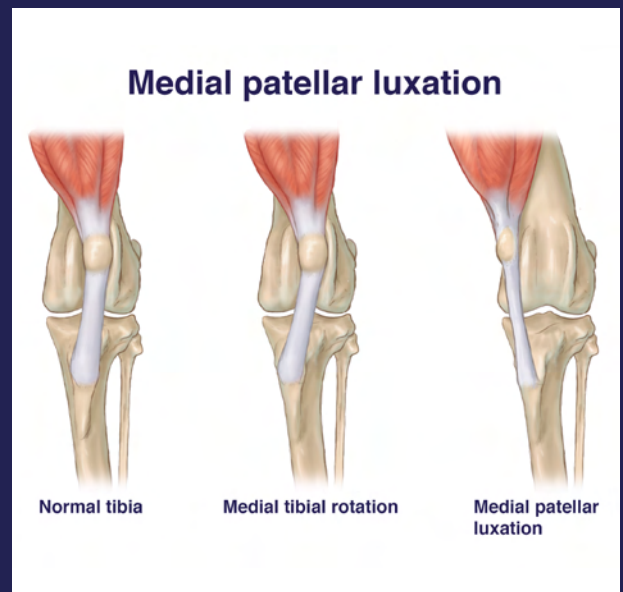


Figure 1 - An illustration depicting the normal alignment of the tissues comprising the joint (left), the effects of medial rotation of the tibia (middle), and medial luxation of the patella (right).

“ Surgical treatment of patellar luxation has two goals: 1) to return the patella to its proper position, and 2) to realign the other components of the stifle joint to keep it in this position. ”

### Treatment

The recommended treatment for a dog with patellar luxation depends on the grade of the luxation and the dog's age. Dogs that are not lame can simply be monitored for any changes that would indicate an increase in the severity of the luxation; surgery is not recommended for these animals. However, surgery is recommended for any dog that is lame and especially for those whose bones are still growing.

Surgical treatment of patellar luxation has two goals: 1) to return the patella to its proper position, and 2) to realign the other components of the stifle joint to keep it in this position. A veterinary surgeon may use a combination of techniques and procedures to achieve these goals. These include recentering the part of the tibia (shin) bone to which the patellar ligament attaches, cutting or reinforcing the ligaments on the sides of the joint, deepening the trochlear groove on the femur to increase the likelihood that the patella will remain within that groove, and shortening and realigning the tibia and or femur.

Dogs undergoing surgery should be walked only on a leash for up to six weeks after the procedure to give the joint sufficient time to recover. After that, the dog should be brought back up to his/her regular speed slowly, so as not to reinjure the area. Veterinarians may prescribe antiinflammatory drugs to help control pain following surgery.

Surgery is usually very successful in restoring normal activity in dogs with Grades III luxations. Because of their small size, Westies tend to have a higher success rate than large breed dogs. Dogs with Grade IV luxations may not return to normal activity, even after surgery. As many as 50% of all dogs undergoing surgery may have incidental Grade I luxations afterwards. Although arthritis cannot be avoided by surgery, it may not be as severe as if the patella had remained luxated.

### Degenerative Joint Disease – A Consequence of Patellar Luxation

Degenerative joint disease, also called osteoarthritis, results from the breakdown of the bones and cartilage that make up a joint. During the development of degenerative joint disease, the cartilage that normally serves a cushioning function between bones, loses this ability. This often initiates inflammation of the cells that line the joint (synovium) and the surrounding joint capsule. The inflammatory mediators released by these tissues adversely affect the cartilage and any ligaments within the joint, resulting in loss of cartilage cells, thickening of ligaments, joint pain, stiffness and reduced range of motion. As the pain makes it difficult to move, the muscles may lose some of their size and strength.

### Trochlear block resection and tibial tuberosity transposition

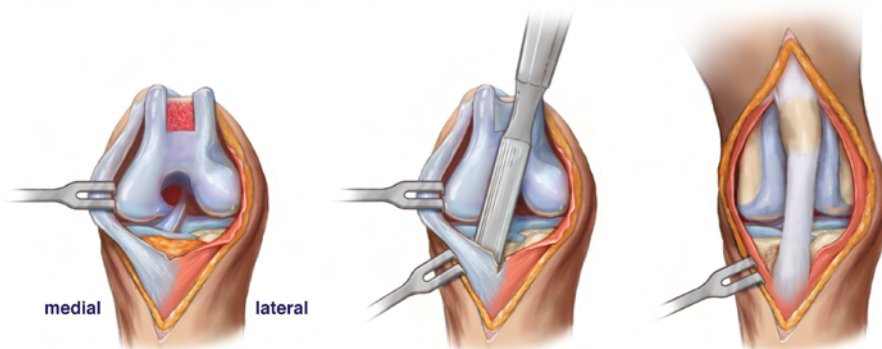


Figure 2 - An illustration depicting trochlear block resection and transposition of the tibial tuberosity in a dog with medial patellar luxation.

## Current Research About Luxation of the Patella

Although there has not been a lot of research performed in the past decade on luxation of the patella in dogs, three recent studies would seem to be of most interest, as they concern a potential predisposition to develop the condition and the results of different types of treatments.

Wangdee C, Theyse LFH, Hazewinkel HAW. Proximo-distal patellar position in three small dog breeds with medial patellar luxation. *Vet Comp Orthop Traumatol* 28: 270-273, 2015.

It has been hypothesized that medial patellar luxation is associated with a high proximal position of the patella in the trochlear groove. In this study, the ratio of the length of the patellar ligament to the length of the patella was determined from radiographs of small breed dogs with and without medial patellar luxation. This ratio first was evaluated using radiographs obtained at five different stifle angles to determine the best angle to use to measure the ratio. Having done this, the ratio was then calculated for dogs with normal stifles as well as dogs with grades I, II and III medial patellar luxations. The ratio was the same for all three breeds of dog (Pomeranian, Chihuahua and Toy poodle), regardless of whether the stifle was normal or affected by medial patellar luxation. As a result, it appears that proximo-distal position of the patella is not associated with the condition, which means that length of the patellar ligament does not play a role in the development of the condition.

Clerfond P, Huneault L, Dupuis J, Moreau M, Auger J. Unilateral or single-session bilateral surgery for correction of medial patellar luxation in small dogs: Short and long-term outcomes. *Vet Comp Orthop Traumatol* 27: 484-490, 2014.

Because medial patellar luxation often occurs bilaterally in small breed dogs, veterinary surgeons have questioned whether it is better to perform the surgery on both legs in a single surgical session or to correct each leg in individual surgery sessions. This study was designed to answer that question by comparing overall, minor and major complication rates for dogs undergoing both surgeries in a single session with those for dogs have their condition treated in two separate surgery sessions. The authors concluded that there were no differences in complication rates, short-term or long-term outcomes between the two groups. Furthermore, while the anesthesia and surgical times were longer for the dogs undergoing bilateral corrective surgery, they were less than doubled. The results of this study suggest that bilateral single-session surgery can be recommended for dogs with bilateral medial patellar luxation.

Cashmore RG, Havlicek M, Perkins NR, James DR, Fearnside SM, Marchevsky AM, Black AP. Major complications and risk factors associated with surgical correction of congenital medial patellar luxation in 124 dogs. *Vet Comp Orthop Traumatol* 27: 263-270, 2014.

This study was performed to describe the major complications occurring after surgical correction of congenital medial patellar luxation in dogs and to identify the risk factors associated with the development of these complications. The authors determined that major complications occurred in 18.5% of the procedures, with failure of stabilization implants being the most common complication. Other major complications were patellar relaxation and avulsion of the tibial tuberosity. The likelihood of the latter complication was increase significantly when a single Kirshner wire was used in the procedure rather than a pair of wires. Furthermore, the risk of patellar relaxation increased substantially when trochleoplasty (deepening of the trochlear groove) was not performed in combination with surgically repositioning of the tibial tuberosity.

## *Acknowledgements*

Mr. Matthew Crotts, a medical illustrator in Educational Resources, created the illustrations used in this chapter, and Dr. Sam Franklin in the Department of Small Animal Medicine & Surgery provided input and guidance for the illustrations. Both Mr. Crotts and Dr. Franklin are in the College of Veterinary Medicine at the University of Georgia.

## *Relevant References*

- Bevan JM, Taylor RA. Arthroscopic release of the medial femoropatellar ligament for canine medial patellar luxation. *J Am Anim Hosp Assoc.* 2004 Jul-Aug;40(4):321-30.
- Bound N, Zakai D, Butterworth SJ, Peard M. The prevalence of canine patellar luxation in three centres. Clinical features and radiographic evidence of limb deviation. *Vet Comp Orthop Traumatol.* 2009;22(1):32-7.
- Campbell CA, Horstman CL, Mason DR, Evans RB. Severity of patellar luxation and frequency of concomitant cranial cruciate ligament rupture in dogs: 162 cases (2004-2007). *J Am Vet Med Assoc.* 2010 Apr 15;236(8):887-91.
- Cashmore RG, Havlicek M, Perkins NR, James DR, Fearnside SM, Marchevsky AM, Black AP. Major complications and risk factors associated with surgical correction of congenital medial patellar luxation in 124 dogs. *Vet Comp Orthop Traumatol.* 2014;27(4):263-70.
- Clerfond P, Huneault L, Dupuis J, Moreau M, Auger J. Unilateral or single-session bilateral surgery for correction of medial patellar luxation in small dogs: short and long-term outcomes. *Vet Comp Orthop Traumatol.* 2014;27(6):484-90.
- Daems R, Janssens LA, Béosier YM. Grossly apparent cartilage erosion of the patellar articular surface in dogs with congenital medial patellar luxation. *Vet Comp Orthop Traumatol.* 2009;22(3):222-4.
- Dokic Z, Lorinson D, Weigel JP, Vezzoni A. Patellar groove replacement in patellar luxation with severe femoro-patellar osteoarthritis. *Vet Comp Orthop Traumatol.* 2015;28(2):124-30.
- Fujii K, Watanabe T, Kobayashi T, Hayashi K. Medial ridge elevation wedge trochleoplasty for medial patellar luxation: a clinical study in 5 dogs. *Vet Surg.* 2013 Aug;42(6):721-6.
- Gibbons SE, Macias C, Tonzing MA, Pinchbeck GL, McKee WM. Patellar luxation in 70 large breed dogs. *J Small Anim Pract.* 2006 Jan;47(1):3-9.
- Harasen G. Patellar luxation: pathogenesis and surgical correction. *Can Vet J.* 2006 Oct;47(10):1037-9.
- Johnson AL, Broaddus KD, Hauptman JG, Marsh S, Monsere J, Sepulveda G. Vertical patellar position in large-breed dogs with clinically normal stifles and large-breed dogs with medial patellar luxation. *Vet Surg.* 2006 Jan;35(1):78-81.
- Kalf S, Butterworth SJ, Miller A, Keeley B, Baines S, McKee WM. Lateral patellar luxation in dogs: a retrospective study of 65 dogs. *Vet Comp Orthop Traumatol.* 2014;27(2):130-4.
- Langenbach A, Marcellin-Little DJ. Management of concurrent patellar luxation and cranial cruciate ligament rupture using modified tibial plateau levelling. *J Small Anim Pract.* 2010 Feb;51(2):97-103.
- Mostafa AA, Griffon DJ, Thomas MW, Constable PD. Proximodistal alignment of the canine patella: radiographic evaluation and association with medial and lateral patellar luxation. *Vet Surg.* 2008 Apr;37(3):201-11.
- Pugliese LC, Pike FS, Aiken SW. Distal tibial tuberosity translation using TTA implants for the treatment of patella alta in large breed dogs. Surgical technique and clinical outcome. *Vet Comp Orthop Traumatol.* 2015;28(4):274-81.
- Segal U, Or M, Shani J. Latero-distal transposition of the tibial crest in cases of medial patellar luxation with patella alta. *Vet Comp Orthop Traumatol.* 2012;25(4):281-5.
- Towle HA, Griffon DJ, Thomas MW, Siegel AM, Dunning D, Johnson A. Pre- and postoperative radiographic and computed tomographic evaluation of dogs with medial patellar luxation. *Vet Surg.* 2005 May-Jun;34(3):265-72.
- Wangdee C, Theyse LF, Hazewinkel HA. Proximo-distal patellar position in three small dog breeds with medial patellar luxation. *Vet Comp Orthop Traumatol.* 2015;28(4):270-3.
- Yasukawa S, Edamura K, Tanegashima K, Seki M, Teshima K, Asano K, Nakayama T, Hayashi K. Evaluation of bone deformities of the femur, tibia, and patella in Toy Poodles with medial patellar luxation using computed tomography. *Vet Comp Orthop Traumatol.* 2016 Jan 13;29(1):29-38.
- Yeadon R, Fitzpatrick N, Kowaleski MP. Tibial tuberosity transposition-advancement for treatment of medial patellar luxation and concomitant cranial cruciate ligament disease in the dog. Surgical technique, radiographic and clinical outcomes. *Vet Comp Orthop Traumatol.* 2011;24(1):18-26.