

Musculoskeletal System

Legg-Calvé-Perthes Disease

Legg-Calvé-Perthes disease is a debilitating condition that occurs in young children and purebred dogs, including Westies. The condition develops as the result of death of the cells that comprise the head of the thigh bone (femur) that inserts into the hip joint. Because this process occurs without any evidence of infection, the condition also is called aseptic femoral head necrosis. This condition was first identified in children more than a century ago by three orthopedic surgeons, and is named after them.

Bone Growth and Skeletal Maturation

Dogs, like other mammals, are born with an immature skeletal system. When an animal is developing in utero, their bones are made entirely of cartilage. Normally, the cartilaginous bones in the dog's legs grow and mature using a process known as "endochondral ossification." During this process, the cartilage becomes calcified from the center of the bone outward. As this occurs, a thin layer of bone is laid around the shaft of the bone (also known as the diaphysis). Bone marrow, which contains blood vessels, stem cells and maturing blood cells, develops inside the forming bone. Eventually, immature bone is formed as a lacey, woven matrix. The ends of the bones, or epiphyses, remain as cartilage and continue to grow until the animal matures. The area where the cartilaginous epiphysis meets the boney diaphysis meet is known as the growth plate. The bone increases in length from the growth plate, and eventually replaces the cartilage with bone both at the growth plate and within the epiphysis. In fact, the epiphysis has its own center of bone development, or ossification. Eventually, immature woven bone is remodeled into mature regular bone.

As the dog matures, the growth plates slow down and eventually cease activity. At this point, the bones stop growing. Depending on the breed, this maturation of the skeleton and bones generally occurs between 1 and 2 years of age. It is important to realize that all bone, in animals of any age, is "alive" – made up of cells, using nutrients and oxygen from the circulation, responding to demands for support and strength, constantly renewing itself, and capable of repairing injuries.

Bone growth is a very complex and well regulated activity. The genome of each dog contains instructions that direct the function of bone and cartilage cells, that regulate the organization of these cells into bones, and for the orderly growth of the skeleton to support the dog's activities. The proper formation of bone is heavily dependent on an adequate supply of nutrients such as protein, calcium and several other minerals, as well as the activity of a few vitamins and hormones. Bone formation is also controlled by the growth of blood vessels in and around the bone and in the covering of bone, the periosteum.

The Pathogenesis of Legg-Calvé-Perthes Disease

Because bone is a living tissue, it is vulnerable to a variety of diseases, ranging from developmental and congenital problems to cancer, infection, metabolic, or biochemical problems. Legg-Calvé-Perthes is classified as a developmental orthopedic (bone-related) disease.

Each stage of bone development requires healthy blood vessels to bring nutrients, including oxygen, to the working cells and carry waste from those cells. In Legg-Calvé-Perthes disease, blood flow to the developing bone in the head of the femur is disrupted. As a result, the cartilage and bone cells that rely on

<u>Common Clinical Findings</u>
Small Breed Dogs
4-11 Months of Age
Lameness and Pain
Abnormal Femoral Head on Radiographs

Legg-Calvé-Perthes disease

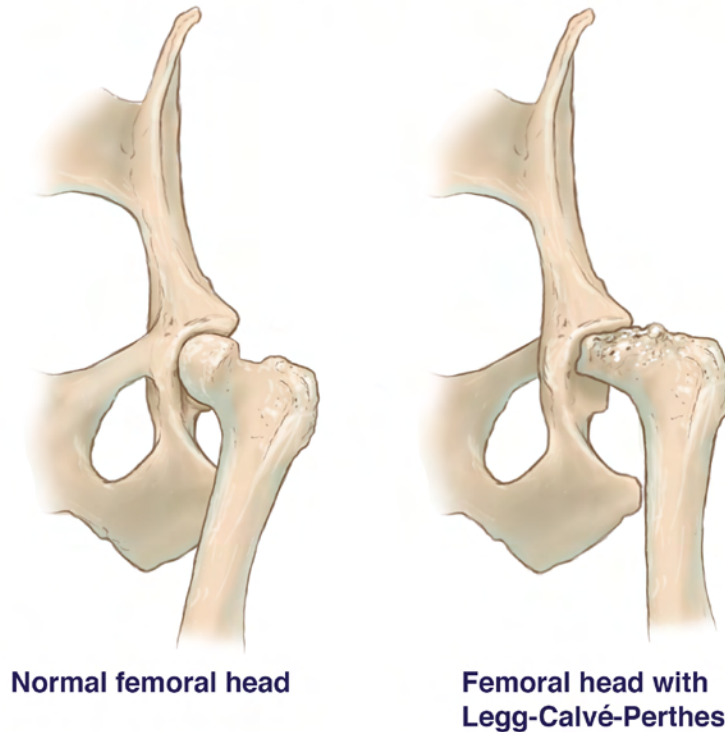


Figure 1 - In this illustration, the normal well-rounded head of the femur (left) fits well in the hip joint, whereas this is not the case with the abnormal femoral head of a dog with Legg-Calvé-Perthes disease (right).

that blood fail to get the nutrients they need, and consequently they die (also known as “necrosis”). Consequently, the head(s) of the femurs do not properly develop and are weak. As a result of this bony weakness, the heads of the femurs in dogs with Legg-Calvé-Perthes may fracture, even with normal activity. The interruption in blood flow that appears to be the inciting cause of Legg-Calvé-Perthes is temporary, because the bone will eventually heal itself and remodel. However, this remodeling leaves the femoral head deformed and leads to arthritis and pain for the patient.

The exact cause for the disruption in blood flow to the femoral head is not known, even though this disease has been observed in people and in animals for more than a century. Theories include destruction of the growth plate, repeated blockage of blood flow, compression of the veins in the area, effects of sex hormones (in people, boys are more affected than girls), infection of the hip joint or increased pressure in the joint. A genetic component is suspected because several breeds are overrepresented in presentation, including Westies.

Clinical Signs

Legg-Calvé-Perthes disease typically affects smallbreed dogs, with clinical signs becoming apparent between four and eleven months of age; males and females are at equal risk. Only 12 to 16% of dogs have both legs affected. Patients experiencing these bony changes will be irritable, may limp and may be in pain. As the disease progresses, the gluteal and quadriceps muscles may atrophy, making them appear smaller. In 6 to 8 weeks, the dog may not put weight on the affected limb at all.

Diagnosis

The principal diagnostic tool for Legg-Calvé-Perthes disease is an xray or radiograph. Veterinarians look for increased space in the hip joint of the affected leg, decreased density of the bone (giving a grey appearance instead of a strong white), subtle or overt fracture of the head of the femur, and possible dislocation of the hip joint (subluxation). In early stages, affected dogs will experience pain when a veterinarian

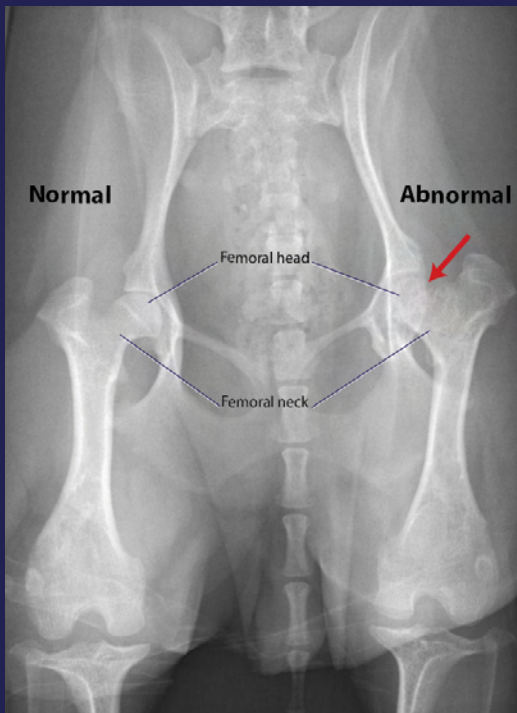
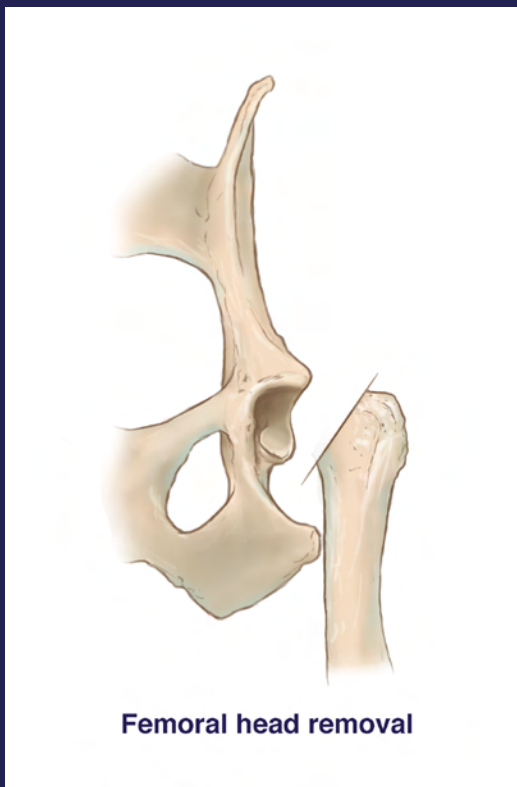


Figure 2 - A radiograph of the rear legs and hip joints of a dog with Legg-Calvé-Perthes disease. The head and neck of the femur are normal on one leg, but abnormal on the affected leg.



Femoral head removal

Figure 3 - This illustration depicts the angle at which the affected femoral neck is transected as part of the treatment of Legg-Calvé-Perthes disease in a dog.

“ In Legg-Calvé-Perthes disease, blood flow to the developing bone in the head of the femur is disrupted. ”

manipulates the limb outward away from the body. There also will be restricted limb motion, and possibly a grating feeling or sound in the hip joint (crepitus).

Figure 2, a radiographic image of an affected 10 month old dog (not a Westie), is a very good example of aseptic necrosis of the femoral head. At the arrow, there is degeneration of the top of the femur and detachment (subluxation) from the hip socket.

Treatment/Prognosis/Prevention

Treatment for Legg-Calvé-Perthes is surgical removal of the femoral head and neck, the section of bone right under the head. Once the surgery is completed, aftercare involves gently exercising the dog's legs by walking, and then running and swimming. The exercise encourages the growth of a fibrous false joint. The scar tissue that forms replaces the head of the femur and fits into the hip bone. While this procedure may seem dramatic, dogs undergoing the procedure often have full use of the leg in as little as four weeks.

This is dependent, however, on the degree of bony changes in the femur and hip joint before surgery, and may vary by individuals. Surgery relieves the pain and lameness in more than 80% of dogs with Legg-Calvé-Perthes disease, regardless of the progression of the condition or age of the patient. Proper surgical technique is critical; many veterinarians are very experienced with removing the affected femoral head.

Without surgery, dogs with Legg-Calvé-Perthes disease can be kept comfortable with rest, the judicious use of antiinflammatory drugs and medication to control pain, and attention proper nutrition (to promote natural healing). However, lameness resolves with this course of treatment in less than 25% of animals.

Current Research About Legg-Calvé-Perthes Disease

Unfortunately, there has not been much research on canine Legg-Calvé-Perthes disease in recent years. Although the disease was identified in dogs more than 50 years ago, only a handful of studies have been done to explore the causes and treatments for the condition in recent years. In this section, we review four recent studies about the disease.

Starr-Moss AN, Nowend KL, Alling KM, Zepp EJ and Murphy KE. Exclusion of COL2A1 in canine Legg-Calvé-Perthes disease. *Animal Genetics*. 1365-2052.2011.

Given that Legg-Calvé-Perthes disease in dogs of small stature is very similar to the same condition in people, in this study the investigators hypothesized that a mutation in the COL2A1 that is associated with the disease in people might exist in West Highland White Terriers. To test this hypothesis, genomic DNA was extracted from blood from dogs with and without the disease. To the investigators' surprise, there was no co-segregation of a mutation (i.e., single nucleotide polymorphism) with the presence of the disease. This finding suggests that a mutation in this gene is not responsible for Legg-Calvé-Perthes disease in West Highland White Terriers.

Isola, M, Zotti, A, Carnier, E, Baroni, E, Busetto, R, "Dualenergy xray absorptiometry in canine Legg-Calvé-Perthes Disease" *Journal of Veterinary Medicine* 52:40710, 2005

In this study, the investigators used a new diagnostic tool that has been used in human hospitals to quantify bone density to compare the density of affected and non-affected bones in dogs with Legg-Calvé-Perthes disease. This technique, called dualenergy xray absorptiometry, is used to provide precise data about mineral density in bones. The researchers hypothesized that differences would be apparent using this technique and that it might be a way to track the progress of boneweakening diseases and potentially diagnose such problems earlier than currently is possible. However, there were no significant differences in mineral density between the dogs' affected with the disease and non-affected legs. The researchers attributed this lack of difference to bone remodeling in the affected leg.

LeFond, E, Breur, G, Austin, C. Breed susceptibility of developmental orthopedic diseases in dogs. *Journal of the American Animal Hospital Association* 38: 467-477, 2002

In this study, veterinary teaching hospital medical records from 1986 to 1995 were reviewed, and the susceptibilities of different breeds to different developmental orthopedic disorders were ranked. The results of that study determined that West Highland White Terriers are 33.2 times more likely to have Legg-Calvé-Perthes than mixed breed dogs. Furthermore, of the breeds that were diagnosed with the condition, Westies were the seventh most represented breed. While breed susceptibility suggests a genetic component to the disease, the researchers pointed out that "the ultimate method to characterize genetic etiology for a disease is the determination of its heritability and mode of inheritance. Consequently, the best way to determine which mutations are associated with the disease would be to map the genome of Westies.

Brenig B, Leeb T, Jansen S, Kopp T. Analysis of blood clotting factor activities in canine Legg-Calvé-Perthes' disease. *J Vet Intern Med*. 1999 Nov-Dec;13(6):570-3.

Legg-Calvé-Perthes has been linked to overactive blood clotting in humans, with the end result being clots that block the blood vessels that normally supply the head of the femur, causing the death of cells in that part of the bone. In an effort to determine the potential role of blood clotting in dogs with Legg-Calvé-Perthes disease, the investigators in this study measured clotting factors in 18 dogs with the disease. Because all results were within normal limits, it appears that factors other than clotting contribute to the development of the condition in dogs.

Acknowledgements

Mr. Matthew Crotts, a medical illustrator in Educational Resources, created the illustrations used in this chapter, and Dr. Sam Franklin in the Department of Small Animal Medicine & Surgery provided input and guidance for the illustrations. Both Mr. Crotts and Dr. Franklin are in the College of Veterinary Medicine at the University of Georgia.

Relevant References

Alpaslan AM, Aksoy MC, Yazici M. Interruption of the blood supply of femoral head: an experimental study on the pathogenesis of Legg-Calve-Perthes Disease. *Arch Orthop Trauma Surg.* 2007 Aug;127(6):485-91.

Brenig B, Leeb T, Jansen S, Kopp T. Analysis of blood clotting factor activities in canine Legg-Calvé-Perthes' disease. *J Vet Intern Med.* 1999 Nov-Dec;13(6):570-3.

Demko J, McLaughlin R. Developmental orthopedic disease. *Vet Clin North Am Small Anim Pract.* 2005 Sep;35(5):1111-35, v. Review.

Isola, M, Zotti, A, Carnier, E, Baroni, E, Busetto, R, "Dualenergy xray absorptiometry in canine LeggCalvePerthes Disease" *Journal of Veterinary Medicine* 52:40710, 2005

Isola, M, Zotti, A, Carnier, E, Baroni, E, Busetto, R, "Dualenergy xray absorptiometry in canine LeggCalvePerthes Disease" *Journal of Veterinary Medicine* 52:40710, 2005

LeFond, E, Breur, G, Austin, C, "Breed susceptibility of developmental orthopedic diseases in dogs" *Journal of the American Animal Hospital Association* 38: 467-477, 2002

Liu SL, Ho TC. The role of venous hypertension in the pathogenesis of Legg-Perthes disease. A clinical and experimental study. *J Bone Joint Surg Am.* 1991 Feb;73(2):194-200.

Mickelson MR, McCurbin DM, Awbrey BJ, Maynard JA, Martin RK. Legg-Calvé-Perthes disease in dogs: a comparison to human Legg-Culvé-Perthes disease. *Clin Orthop Relat Res.* 1981 Jun;(157):287-300.

Scherzer C, Windhagen H, Nellesen J, Crostack HA, Rohn K, Witte F, Thorey F, Fehr M, Hauschild G. Comparative structural analysis of the canine femoral head in Legg-Calvé-Perthes disease. *Vet Radiol Ultrasound.* 2009 Jul-Aug;50(4):404-11.

Starr-Moss AN, Nowend KL, Alling KM, Zepp EJ and Murphy KE. Exclusion of COL2A1 in canine Legg-Calves'- Perthes disease. *Animal Genetics.* 1365-2052. 2011.

Vasseur PB, Foley P, Stevenson S, Heitter D. Mode of inheritance of Perthes' disease in Manchester terriers. *Clin Orthop Relat Res.* 1989 Jul;(244):281-92.